

# Distal perfusion cannula on VA-ECMO: do not blindly trust! A case report

Rodrigo Diaz,<sup>1</sup> Marta Velia Antonini<sup>2,3</sup>

<sup>1</sup>Pabellon Central, Red Salud Santiago, Pabellon Central, Santiago, Chile; <sup>2</sup>Anesthesia and Intensive Care Unit, Bufalini Hospital - AUSL della Romagna, Cesena; <sup>3</sup>Department of Biomedical, Metabolic and Neural Sciences, University of Modena & Reggio Emilia, Modena, Italy

## Abstract

Distal perfusion cannulas, DPCs, are increasingly used to prevent limb ischemia, frequent and potentially serious complication on peripheral veno-arterial extracorporeal membrane oxygenation (V-A ECMO) support. We report the case of a patient treated with femoro-femoral V-A ECMO who developed a sudden, significant asymmetric decrease in cannulated limb regional oxygen saturation, rSO<sub>2</sub>, signal, despite the presence of a DPC. This finding, noticed within 6 hours after the implementation of extracorporeal cardiopulmonary resuscitation (ECPR) in a patient experiencing refractory intra-hospital cardiac arrest (IHCA), suggested ongoing limb ischemia. After careful monitoring, a clot

was detected in the line supplying DPC, which appeared completely kinked at dressing removal. Line patency and reperfusion were promptly re-established. No additional ischemic episodes occurred, and the patient was successfully weaned from extracorporeal support, and experienced full functional recovery, with no sensory or motor deficit.

This case highlights the strict need for a careful, continuous monitoring of limb perfusion during V-A ECMO, even if limb perfusion through DPC is implemented, in order to prevent severe limb complications, negatively impacting on outcome.

## Introduction

Limb ischemia represents a relatively frequent and serious complication of peripheral configuration femoro-femoral V-A ECMO support,<sup>1</sup> even if a really variable incidence has been reported in the published literature.<sup>1</sup> According to the data reported to the Extracorporeal Life Support Organization (ELSO) Registry (International Summary, October, 2022, reporting data through 2021), the incidence of limb ischemia in adult patients is 4.1% for extracorporeal cardiac support, and 4.7% for extracorporeal cardiopulmonary resuscitation (ECPR).<sup>2</sup>

The cannulated artery could be significantly occluded by the return catheter itself; this could impair or completely prevent distal flow, particularly as the ratio between arterial cannula diameter to cannulated artery increases.<sup>3,4</sup> Anyway, comparable incidence of limb ischemia has been described with different cannulation techniques: percutaneous, surgical, and hybrid.<sup>5</sup> In fact, other conditions could possibly induce or contribute to the development of limb ischemia in this setting have been reported, particularly selective perfusion of deep femoral artery, damage of the vessels associated to cannulation procedure, arterial vasospasm, ab-extrinsico compression of the artery due to the presence of the venous cannula, or due to the presence of the arterial cannula, and pre-existing atherosclerotic arterial disease.<sup>1</sup> Moreover, hemodynamic instability, with inadequate peripheral perfusion, may furtherly contribute to limb ischemia development,<sup>1,6</sup> as high dosage of vasopressors.<sup>1</sup> A summary of major factors potentially contributing to limb ischemia development in patients on veno-arterial ECMO is included in Figure 1.

If unrecognized, left untreated or if unsuccessfully approached, limb ischemia could potentially lead to major morbidity; fasciotomy or limb amputation may eventually be required, and limb ischemia might impact on mortality and long term outcome/quality of life.<sup>1,2,5,7</sup> A late reperfusion may induce rhabdomyolysis or ischemia reperfusion injury.<sup>7</sup>

The occurrence of cannulated limb ischemia during the ECMO run, and the occurrence of related complications, could be effectively reduced by preventive insertion of a distal perfusion cannula, DPC,<sup>1,6-10</sup> to be supplied with blood from the extracorporeal circuit, diverged from the arterial cannula.<sup>11</sup>

Correspondence: Rodrigo Diaz, Pabellon Central, Red Salud Santiago, Av. Libertador Bernardo O'Higgins 4850, Santiago, Estación Central, Región Metropolitana, Chile.

E-mail: rodrigoa.diaz@redsalud.cl

Key words: ECMO; ECLS; ECPR; NIRS; distal perfusion cannula.

Conflict of interest: the Authors declare no conflict of interest.

Ethics approval and consent to participate: no ethical committee approval was required for this case report by the Department, because this article does not contain any studies with human participants or animals. Informed consent was obtained from the patient included in this study.

Patient consent for publication: the patient gave his written consent to use his personal data for the publication of this case report and any accompanying images.

Availability of data and materials: all data underlying the findings are fully available.

Received: 5 April 2023.

Accepted: 22 April 2023.

Publisher's note: all claims expressed in this article are solely those of the authors and do not necessarily represent those of their affiliated organizations, or those of the publisher, the editors and the reviewers. Any product that may be evaluated in this article or claim that may be made by its manufacturer is not guaranteed or endorsed by the publisher.

©Copyright: the Author(s), 2023

Licensee PAGEPress, Italy

Acute Care Medicine Surgery and Anesthesia 2023; 1:15

doi:10.4081/amsa.2023.15

This work is licensed under a Creative Commons Attribution-NonCommercial 4.0 International License (CC BY-NC 4.0).

The reperfusion flow could be antegrade, commonly obtained inserting a DPC in the ipsilateral superficial femoral artery (SFA) or in the ipsilateral common femoral artery (CFA), accessed with percutaneous or surgical technique.<sup>7</sup> An alternative strategy to reperfuse the limb is the insertion of a small cannula in the ipsilateral posterior tibial artery (PTA), arising a retrograde flow.<sup>10</sup> Best timing of DPC placement is not defined, and aggressive strategies considering insertion at the time of ECMO cannulation, or immediately after (within few hours, or anyway before any evidence of impending ischemia) have been successfully implemented.<sup>1</sup>

Regional hemoglobin oxygen saturation (rSO<sub>2</sub>), interpreted in the context of clinical setting, has been previously described as an accurate, reliable monitoring tool to support real-time diagnosis of limb ischemia during ECMO support,<sup>1,12,13</sup> and has been advocated as a standard of care in this population, even if somatic monitor has not been largely validated to diagnose limb ischemia, and specific cutoff values still need to be defined.<sup>12</sup>

Near-infrared spectroscopy (NIRS) somatic oximetry uses the near-infrared region of the electromagnetic spectrum at wavelengths absorbed by hemoglobin (730 and 810 nm), providing a non-invasive real-time continuous monitoring of rSO<sub>2</sub>. These data could be used to assess the balance between O<sub>2</sub> delivery and O<sub>2</sub> consumption, and, integrated with clinical data, could be used to evaluate tissue oxygenation and to support prompt identification of tissue hypoxia. If consistent drop in rSO<sub>2</sub>, or if a significant differential value between cannulated and non-cannulated are detected,<sup>12</sup> this should prompt for a differential diagnosis to be implemented, followed by early interventions, thus potentially reducing the occurrence of irreversible injury.



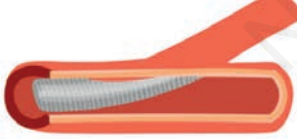
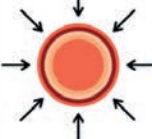


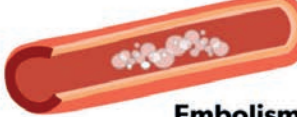

We report a case of limb ischemia in a patient on V-A ECMO support, occurring despite ongoing reperfusion of the cannulated limb, early detected through rSO<sub>2</sub> monitoring.

The patient consented to publication of anonymized images and details of the case. The CARE guidelines: consensus-based clinical

case reporting guideline development (CARE) was used for reporting.<sup>14</sup>

## Case Report

A 58-year-old male patient with no previous history of risk factors for cardiovascular disease was admitted to the emergency department for moderate thoracic pain, accompanied by severe neurovegetative signs. An electrocardiogram performed at admittance showed ST segment elevation in the inferior leads, and reciprocal ST segment depression in the lateral leads, suggesting ongoing acute inferior wall myocardial infarction. The patient was transferred to the cardiac catheterization laboratory for definitive diagnosis and eventual treatment, but experienced loss of consciousness and cardiac arrest during the transport. Conventional cardiopulmonary resuscitation (cCPR) was immediately initiated, including closed chest compression, multiple external defibrillations, and, epinephrine and amiodarone administration, consistently with advanced cardiac life support protocol in the context of persistent ventricular fibrillation. Once in the cath-lab, mechanical chest compressions was delivered (LUCAS® 3.0 chest compression system), endotracheal intubation achieved, and mechanical ventilation started. Coronary angiography revealed significant occlusion of a (dominant) left circumflex artery (LCx), and uncomplicated percutaneous transluminal coronary angioplasty (PTCA) was performed under cCPR, with successful insertion of a drug eluting stent (XIENCE Sierra™ 3,5 mm x 12 mm), achieving grade 3 Thrombolysis In Myocardial Infarction (TIMI) flow. However, return of spontaneous circulation (ROSC) was not obtained. At this time, 7 cCPR cycles were performed, configuring refractory intra-hospital cardiac arrest (IHCA); thus, we decided to switch from cCPR to eCPR, implemented with no complications through percutaneous, ultrasound guided right

<p><b>Obstruction</b></p> 	<p>Femoral artery obstruction due to the presence of return cannula, impairing (decreasing or completely preventing) distal limb perfusion.</p>	<p><b>Hypotension/Vasoconstriction</b></p> 	<p>Hypoperfusion related to hemodynamic instability and/or requirement for high dosages of vasopressors.</p>
	<p><b>Selective Cannulation</b> Insertion of the return cannula in the SFA, preventing or impairing distal limb perfusion.</p>		<p><b>Acute compartment syndrome</b> Impaired venous and lymphatic drainage with increased compartment pressure and eventual development of acute compartment syndrome might lead to limb ischemia.</p>
<p><b>Compression</b></p> 	<p>Compression ab-extrinsico of the arterial vessels of cannulated limb induced by the presence of drainage and/or return cannula.</p>	<p><b>Arterial Injury</b></p> 	<p>Arterial injury (ie dissection) occurring during cannulation, invasive procedures (ie PCI), or other devices insertion (IABP, percutaneous MCS).</p>
 <p><b>Embolism</b></p>	<p>Arterial air embolism (ie due to air entrance into the circuit) or thromboembolism (ie plaque rupture at cannulation, or thrombotic ECLS complication).</p>		<p><b>Pre-existing disease</b> Atherosclerotic or other vascular disease involving arterial vessels, with impaired peripheral perfusion.</p>

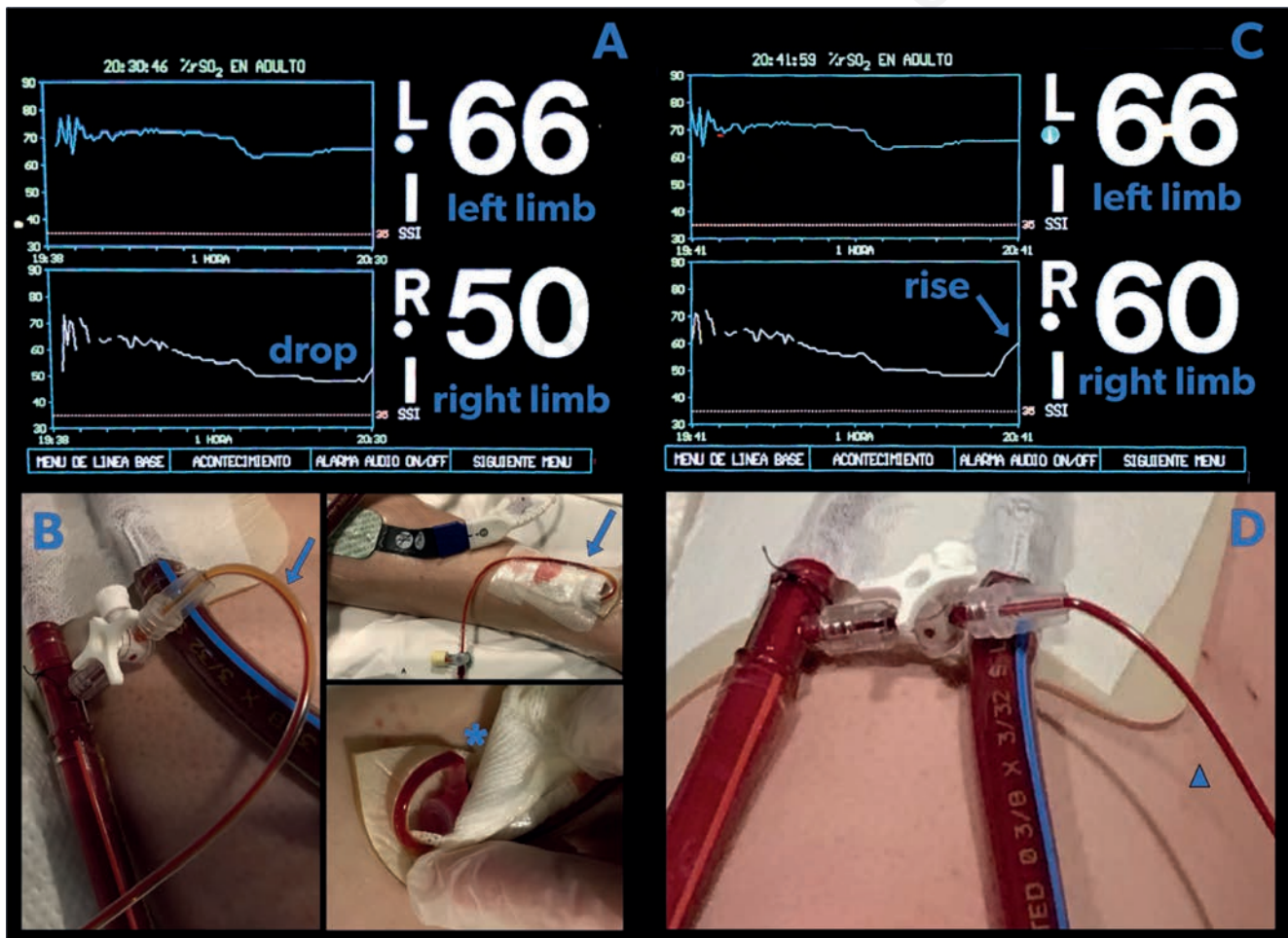
**Figure 1.** Main determinants or co-determinants of limb ischemia during peripheral veno-arterial extracorporeal membrane oxygenation (ECMO); SFA, superficial femoral artery; ECLS, extracorporeal life support; PCI, percutaneous coronary intervention; IABP, intraortic balloon pump; MCS, mechanical circulatory support.

femoral vessels cannulation. After confirmation of proper cannula position, assessed through transesophageal echocardiography (TEE) and fluoroscopy, V-A ECMO support was started, and chest compressions interrupted. TEE also revealed left ventricular systolic dysfunction, moderate to severe mitral valve regurgitation (MVR), bicuspid aortic valve with mild aortic regurgitation (AVR), the presence of vegetations suggestive of infective endocarditis involving both left cardiac valves, and an ascending aortic aneurysms (50 mm).

As per institutional protocol for all adult patients undergoing femoro-femoral VA-ECMO, in the absence of absolute contraindications (e.g. diseased vessel), a 4 Fr catheter (Radifocus®, Terumo) was surgically inserted in the ipsilateral right PTA to provide retrograde limb reperfusion. PTA was exposed through a 5 cm longitudinal incision proximal and posterior to the medial malleolus, and circumferentially isolated, with vessel loops, preserving tibial nerve, then punctured under direct vision about 2 mm distally to the incision, and cannula was inserted with Seldinger technique. After cannulation, DPC was flushed with a solution of 30 mg papaverine in NaCl 0.9%, to prevent vasospasm, then connected to the de-airing port of the arterial cannula with the interposition of a 3-way stopcock. Effective lower extremity

reperfusion was achieved. The cannula was secured and the incision closed with a running suture.

Patient was moved to the cardiac intensive care unit, for post-cardiac arrest care; NIRS was monitored bilaterally through non-invasive somatic sensors placed on medial calfs (INVOS™ Oximeter, Medtronic). Within 6 hours an asymmetric decrease in cannulated limb rSO<sub>2</sub> signal, reduced by up to 22%, compared to basal value (64%) and by up to 24% compared to contralateral limb value (Figure 2A) was noticed, shortly after a nursing procedure. This suggested impaired oxygen supply to oxygen consumption ratio. Distal limb presented cold and pale, compared to contralateral leg; no mottling was observed. At first inspection, a large clot was detected in the line supplying DPC (Figure 2B), which appeared completely kinked at dressing removal (Figure 1B). In the attempt re-establish distal limb perfusion, aspiration has been performed connecting a 20mL luer lock syringe to the free port the 3-ways stopcock previously interposed. The maneuver resulted successful, with immediate clot mobilization and removal, and arterial blood aspiration: distal perfusion cannula patency and limb reperfusion were re-established (Figure 2C), with prompt increase in ipsilateral rSO<sub>2</sub> (Figure 2D). After the procedure, cannulated limb appeared normothermic and pink, with capillary refill time below 2 seconds.



**Figure 2.** A, regional oxygen saturation (rSO<sub>2</sub>) signal, 1 hour trend and instant numerical value, for both cannulated (right) and free (left) limb; value immediately after detection of desaturation. B, Distal perfusion cannula (DPC) connected to the arterial cannula (details in the text); blue arrows: clot detected in the line supplying DPC; blue asterisk: kinking in the line supplying DPC. C, rSO<sub>2</sub> signal, 1 hour trend and instant numerical value, for both cannulated (right) and free (left) limb; value after reperfusion. D, blue triangle: re-established perfusion of DPC.

No additional ischemic episodes occurred; due to improved contractility and hemodynamic status, weaning was performed in 24h. After decannulation, the patient, fully awake and cooperative, did not experienced any sensory or motor deficit.

## Conclusions

Present case highlights the strict need for a careful monitoring of cannulated limb during peripheral V-A ECMO, even if DPC is used, to prevent severe complications which could negatively impact on patient's outcome.  $rSO_2$ , even considering its limitations, could be an effective strategy to provide an immediate, non-invasive, continuous, and relatively low-cost assessment of limb perfusion, easy to be implemented and interpreted by ICU nurses or ECMO specialists. Moreover, somatic regional saturation could potentially overcome the limitations associated with perfusion monitoring based on clinical and echographic evaluation during the ECMO run, as these could be potentially hampered by nonpulsatile or low pulsatile blood flow states on full extracorporeal support, when native heart contractility is severely impaired.

To early detect ongoing limb ischemia, continuous  $rSO_2$  monitoring of both cannulated and free lower limbs through NIRS could be advisable.

## References

1. Bonicolini E, Martucci G, Simons J, et al. Limb ischemia in peripheral veno-arterial extracorporeal membrane oxygenation: a narrative review of incidence, prevention, monitoring, and treatment. *Crit Care* 2019;23:266.
2. Extracorporeal Life Support Organization (ELSO) Registry International Summary, October, 2022, reporting data through 2021. Available from: <https://www.else.org/registry/international-summaryandreports/internationalsummary.aspx> accessed on March 2022
3. Yen CC, Kao CH, Tsai CS, Tsai SH. Identifying the risk factor and prevention of limb ischemia in extracorporeal membrane oxygenation with femoral artery cannulation. *Heart Surg Forum* 2018;21:E018-E022.
4. Yau P, Xia Y, Shariff S, et al. Factors associated with ipsilateral limb ischemia in patients undergoing femoral cannulation extracorporeal membrane oxygenation. *Ann Vasc Surg* 2019;54:60-65.
5. Wilhelm MJ, Inderbitzin DT, Malorgio A, et al. Acute limb ischemia after femoro-femoral extracorporeal life support implantation: A comparison of surgical, percutaneous, or combined vascular access in 402 patients. *Artif Organs* 2022;46:2284-92.
6. Lamb KM, DiMuzio PJ, Johnson A, et al. Arterial protocol including prophylactic distal perfusion catheter decreases limb ischemia complications in patients undergoing extracorporeal membrane oxygenation. *J Vasc Surg* 2017;65:1074-9.
7. Chanan EL, Bingham N, Smith DE, Nunnally ME. Early detection, prevention, and management of acute limb ischemia in adults supported with venoarterial extracorporeal membrane oxygenation. *J Cardiothorac Vasc Anesth* 2020;S1053-0770(20)30178-6.
8. Kaufeld T, Beckmann E, Ius F, et al. Risk factors for critical limb ischemia in patients undergoing femoral cannulation for venoarterial extracorporeal membrane oxygenation: Is distal limb perfusion a mandatory approach? *Perfusion* 2019;34:267659119827231.
9. Ranney DN, Benrashed E, Meza JM, et al. Vascular complications and use of a distal perfusion cannula in femorally cannulated patients on extracorporeal membrane oxygenation. *ASAIO J* 2018;64:328-33.
10. Spurlock DJ, Toomasian JM, Romano MA, et al. A simple technique to prevent limb ischemia during veno-arterial ECMO using the femoral artery: the posterior tibial approach. *Perfusion* 2012;27:141-5.
11. Gajkowski EF, Herrera G, Hatton L, et al. ELSO guidelines for adult and pediatric extracorporeal membrane oxygenation circuits. *ASAIO J* 2022;68:133-52.
12. Kim DJ, Cho YJ, Park SH, et al. Near-infrared spectroscopy monitoring for early detection of limb ischemia in patients on veno-arterial extracorporeal membrane oxygenation. *ASAIO J* 2017;63:613-7.
13. Castro DM, Morris I, Teijeiro-Paradis R, Fan E. Monitoring during extracorporeal membrane oxygenation. *Curr Opin Crit Care* 2022;28:348-359.
14. Gagnier JJ, Kienle G, Altman DG, et al. The CARE guidelines: consensus-based clinical case reporting guideline development. *BMJ Case Rep* 2013;2013:bcr2013201554.